

EMBRYONIC DEVELOPMENT OF THE AMERICAN KESTREL (*FALCO SPARVERIUS*): EXTERNAL CRITERIA FOR STAGING

J.M. PISENTI

Department of Animal Science, University of California, One Shields Avenue, Davis, CA 95616 U.S.A.

G.M. SANTOLO¹

CH2M HILL, Inc., 2485 Natomas Park Drive, Suite 600, Sacramento, CA 95833 U.S.A.

J.T. YAMAMOTO AND A.A. MORZENTI

Department of Animal Science, University of California, One Shields Avenue, Davis, CA 95616 U.S.A.

ABSTRACT.—Descriptions of embryonic development exist for a handful of bird species. Such standard information is essential for the evaluation of species-specific features and detecting abnormal morphology. The American Kestrel (*Falco sparverius*) is a common North American raptor that is frequently used in experimental studies as a model raptor species. We described the normal progression of embryonic development in the American Kestrel. This provides a standard for assessing American Kestrel embryos, and potentially those of other raptors. During the first half of incubation, the developmental progression of American Kestrel embryos corresponded closely to developmental stages established in the chicken (*Gallus domesticus*). Morphological parameters that we measured were correlated significantly with incubation day. These qualitative and quantitative descriptions provide useful benchmarks for determining age and identifying abnormalities of experimentally-treated embryos or embryos of unknown history.

KEY WORDS: *American kestrel; Falco sparverius; avian embryology; embryo development; embryo staging.*

Desarrollo embrionario del cernícalo americano (*Falco sparverius*) criterios externos para su definición

RESÚMEN.—Las descripciones del desarrollo embrionario existen para unas pocas especies. Esta información estandarizada es esencial para la evaluación de las características específicas de una especie y para detectar morfologías anormales. El cernícalo americano (*Falco sparverius*) es una rapaz común de Norteamérica la cual es frecuentemente utilizada en estudios experimentales como una especie sustituto de ave rapaz. Describimos la progresión normal del desarrollo embrionario del cernícalo americano. Esto provee un estándar para evaluar los embriones de esta especie y potencialmente de otras rapaces. Durante la primera mitad de la incubación la progresión del desarrollo de los embriones del cernícalo americano correspondió a las etapas del desarrollo establecidas para *Gallus domesticus*. Los parámetros morfológicos medidos fueron significativamente correlacionados con el día de la incubación. Estas descripciones cualitativas y cuantitativas representan un punto de referencia para determinar la edad e identificar las anomalías de los embriones experimentalmente tratados o cuya historia es desconocida.

[Traducción de César Márquez]

The ability to age embryos accurately and assess normal development in birds is critical to many areas of biological study. Some of the more important applications include monitoring for environmental contaminant effects and determining nu-

tritional requirements for breeding birds. Currently, the most complete and detailed description of avian embryonic development is that done for the domestic chicken, *Gallus domesticus* (Hamburger and Hamilton 1951, Hamilton 1952, Belairs and Osmond 1998). Developmental progressions have also been described for other precocial birds including Ring-necked Pheasant (*Phasianus colchicus*; Hermes and Woodard 1987, Labisky and Opsahl 1958), Mallard (*Anas platyrhynchos*; Caldwell

¹ Corresponding author: Gary M. Santolo, CH2M HILL, Inc., 2485 Natomas Park Dr., Suite 600, Sacramento, CA 95833.

and Snart 1974), Bobwhite Quail (*Colinus virginianus*; Roseberry and Klimstra 1965), domestic chicken, turkey (*Meleagris gallopavo*), and Japanese quail (*Coturnix japonica*) (Abbott 1967), and Adelie Penguin (*Pygoscelis adeliae*, Herbert 1967), as well as a handful of altricial species (Daniel 1956, Bird et al. 1984, Abbott et al. 1991, Hanbidge and Fox 1996) including the American Kestrel (*Falco sparverius*). In studies requiring a finely detailed assessment of development, it is desirable to have species-specific data on which to base comparisons. While gross or extreme embryonic deformities and stunting are generally distinguishable in the absence of a reference, more subtle morphological changes may be overlooked without a normal standard for comparison.

With the exception of Bird et al. (1984), no species from the Falconiformes have been described during embryonic development. This is in spite of the numerous potential applications of such data, including comparative studies, aging of field collected embryos, assessment of abnormal development, and in captive breeding efforts for rare species. In this paper we provide, through measurements, qualitative description, and identification of specific aging criteria, a detailed normal developmental progression of the American Kestrel throughout the incubation period.

METHODS

Animals and Treatments. We obtained captive-bred adult male and female American Kestrels from the Avian Science and Conservation Centre of McGill University (Montreal, Canada). Pedigrees for these birds were known, although the number of generations that were traceable varied among birds (1–4 generations). This group was supplemented by additional male and female American Kestrels we obtained from wild populations in California (Yolo and Solano counties; 38°N, 121°W). We cared for American Kestrels according to animal care protocols approved by the Office of the Campus Veterinarian at UCD.

Prior to the breeding period (early March), we paired 40 each of male and female American Kestrels and placed them in individual breeding pens (approximately 2 m × 2 m × 1.75 m). Most pairs had been together for the previous one or two breeding seasons, and had successfully produced fertile eggs. We maintained breeding pens at ambient temperature (range 0 to 37°C) in a large screen-sided building that provided protection from direct sunlight and rain. The building was equipped with supplemental lighting above the breeding pens, which was controlled by a timer set to coincide with the natural photoperiod. Each pen was equipped with a shelf and a rope perch, and a wooden nest box (entrance hole approximately 7 cm diameter) containing autoclaved pine shavings to a depth of about 5 cm. We maintained birds

on a nutritionally complete commercial raptor diet (Nebraska Bird of Prey Diet, Central Nebraska Packing, North Platte, Nebraska, USA), supplemented with a powdered multivitamin additive (Vionate; ARC Laboratories, Atlanta, Georgia, USA). Each pair was provided with about 100 gm of fresh food daily, and water was provided *ad libitum*.

Egg Collection and Incubation. We observed pairs daily for normal appearance and behavior and we checked nest boxes daily in the late afternoon for occupation by the male and/or female American Kestrel and for newly laid eggs. Due to this collection schedule, some eggs may have been incubated by parent birds for up to 24 hr. However, such a prolonged incubation was unlikely as American Kestrels do not typically incubate until the clutch is nearly complete (typical clutch size was 4–5 eggs). We labeled new eggs using waterproof ink with pen number and Julian date, weighed them, then placed them in sterilized fiber chicken egg flats for immediate transport to cold storage (Heck and Konkel 1991). Eggs were held in cold storage (12.5–13.0°C) for 3–4 d. Just before the start of incubation, we placed the eggs in plastic chicken flats (up to 30 eggs per flat), and fumigated them for one h with formaldehyde gas, followed by one hr in a formaldehyde-neutralizing compound (ammonia gas). During this procedure, the fumigation chamber was heated to 30°C, then cooled to 13°C. After fumigation, we placed the eggs in an egg storage cold box at 13°C for an additional 6 hr (until about 1800 PST on that day), then weighed them again and allowed them to warm at room temperature (22°C) for about 30 min before the start of incubation. We set eggs, air cell up, in plastic set trays designed for pheasant eggs and placed them in a Natureform NOM-125 incubator (Natureform Hatchery Systems, Jacksonville, Florida, USA) at 37.5°C and 55% relative humidity. In a previous study (Santolo et al. 1999), these conditions were shown to promote normal embryonic development and successful hatching of eggs from this colony. Eggs were automatically turned through 90° (45° right to 45° left, etc.) every 15 min. We candled eggs daily, using a variable intensity candler (Lyon's Electric, San Diego, CA, USA), modified with a 2.5 cm diameter black rubber hose taped to the candling mask. This modification served to move the egg further from the heat of the light source. Eggs were candled from both ends, and a record was made of the candling appearance for each egg. This information: (1) allowed early identification of infertile eggs and early dead embryos, and (2) made it possible to identify pre-incubated eggs (those displaying development more advanced than other eggs in the age class). On Day 24 of incubation, we moved all eggs with live embryos into individual hatching baskets (sterilized plastic one pint produce baskets) in a tabletop, forced draft incubator (Lyon's Electric, San Diego, CA, USA), set at 37.5°C, 70–75% relative humidity.

Breakout Examination. We broke out and examined any eggs that showed no sign of embryonic development after 7 d to determine fertility. We also opened eggs if the embryo appeared dead. During the first half of incubation, we selected live embryos for collection based on candling appearance. We usually collected more advanced embryos (i.e., those likely to have been pre-incubated by their parents) during the late growth phase

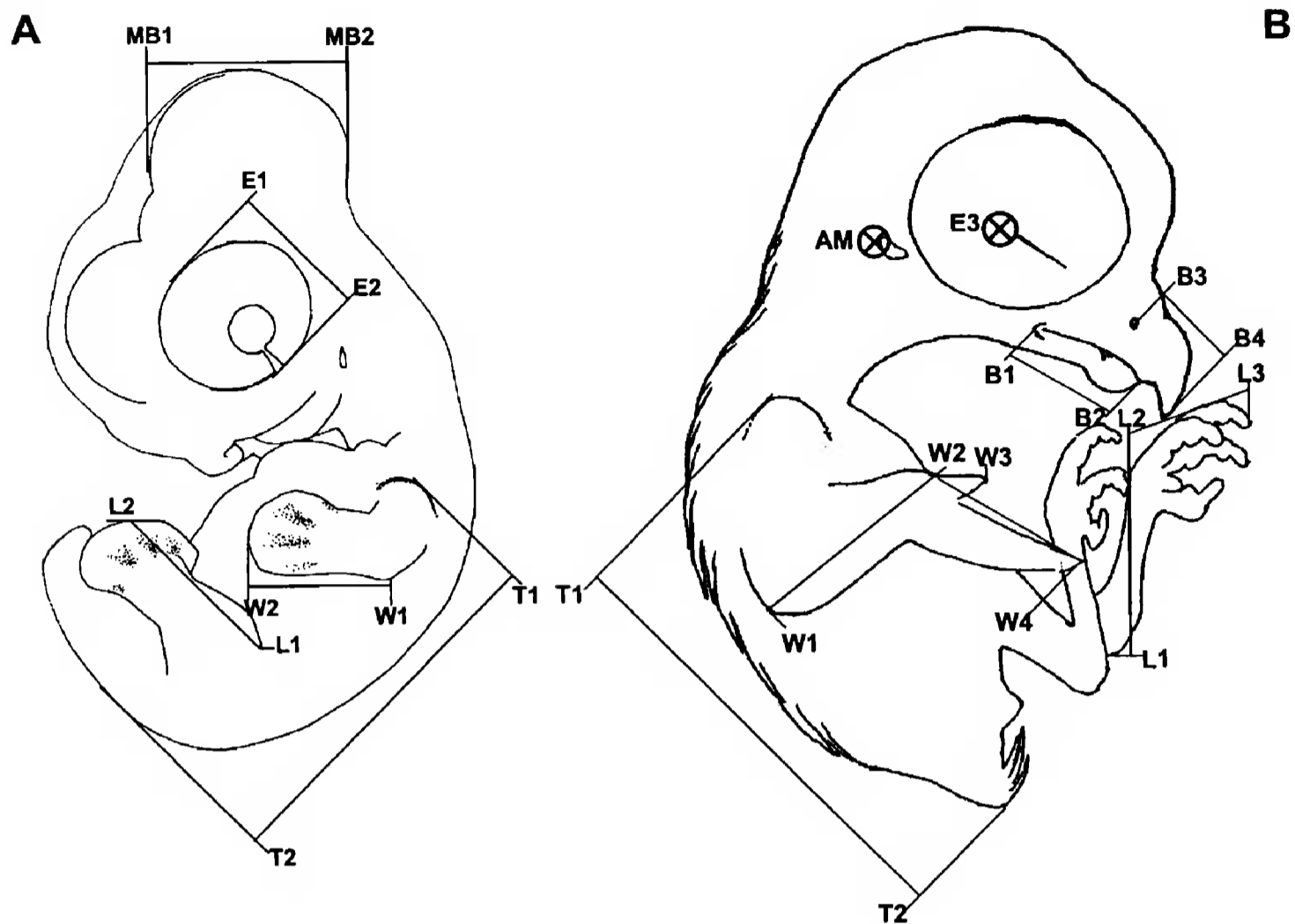


Figure 1. Line drawings showing embryo measurements: A, young embryo: T1 to T2, trunk length; L1 to L2, leg length; W1 to W2, wing length (elbow to tip); E1 to E2, eye diameter; MB1 to MB2, midbrain diameter (across widest section). B, older embryo: L1 to L2, tarsus; W1 to W2, forearm; W2 to W3, alula; W2 to W4, manus; B1 to B2, lower beak; B3 to B4, culmen; E3, approximate eye-to-eye measurement; AM, approximate point of ear-to-ear measurement (width of skull at auditory meatus).

of embryonic development, in order to minimize the effect of pre-incubation on early embryo assessments. We weighed all eggs prior to opening them. For embryo collection, we measured the air cell diameter and then cut the shell open over the air cell and emptied the contents while submerging the egg in deionized water. We removed extraembryonic membranes, then weighed the embryo and placed it in a small dish of clean deionized water. We measured diameter of the air cell to the nearest 0.5 mm with calipers, and measured yolk and albumen mass (to nearest 0.001 g; Mettler Instruments, Hightstown, NJ, USA; model HRIAR), and volume (water displacement). We obtained yolk sac and albumen measurements when these could be reliably isolated from the surrounding water (i.e., no yolk or albumen measurements were made during the first week of incubation, as both materials tended to be difficult to isolate during this period). We made measurements of the head, trunk, and limbs to the nearest 0.5 mm using calipers and a metric ruler (see Fig. 1 for diagrams showing specific measurements). For each age class of embryo, we selected structures based on the degree to which they could be reliably measured and easily identified landmarks. We staged all embryos using standard chicken embryo criteria (Hamburger and Hamilton 1951).

Statistical Analyses. We used simple and second-order

polynomial regression to develop equations for predicting embryo age from measured parameters and ANOVA to measure the quality of the models (SAS Institute 1998).

RESULTS

Nonviable Eggs. Infertile eggs and early embryo mortality are described below and examples are presented in Appendix 1.

Early dead. Very early failures in development will produce a mottled white membrane of varying size with a highly irregular outline spreading across the yolk. The white coloration tends to be most intense at the edge of membrane. If failure occurs slightly later, blood islets, and often parts of the embryo itself, will form. These early dead embryos may appear as a darker region in the center of the membrane.

Infertile. The infertile germ spot is mottled and whitish, with an irregular circular outline, surrounded by a slightly darker band of yolk (width

Table 1. Range of embryo stages found and the number of embryos examined during each day of incubation.

INCUBATION DAY	H & H STAGE ^a	N	RANGE
1	2	2	2-3
2	4	3	3-7
3	8	3	6-10
4	13	3	12-16
5	18	3	18-19
6	20	3	17-21
7	24	4	23-25
8	25	4	25
9	27	4	25-29
10	28	3	27-29
11	30	4	30-31
12	32	4	30-33
13	33	4	32-34
14	35	3	35
15	36	3	36
16	36 +	3	36-37
17	37	3	37
18	38	3	38
19	38	3	37-38
20	39	4	38-40
21	40	4	37-40
22	42	4	40-44
23	44	2	44
24	44	4	44
25	44 +	1	44 +
26	45 -	3	45 -
27	45	3	45-46
28	46	3	46

^a Stage of embryonic development as described for the chicken by Hamburger and Hamilton (1951).

of the darker band is 0.5-1.0 mm). The appearance is very similar to that of the Day 0 blastoderm.

Normal Developmental Stages of the American Kestrel. The text below describes the embryonic development of the American Kestrel, emphasizing key diagnostic features for assessing embryo age and (morphologic) normalcy. Along with descriptive text, each daily account includes the approximate stage (median stage with observed range of stages in parentheses) of the embryo, based on normal stages of the domestic chick (Hamburger and Hamilton 1951; see Table 1). Selected daily accounts correspond to embryo photographs in Appendix 1-4. A minority of the descriptions for some aspects of development are clearly only relevant to living embryos and therefore are not useful in assessing dead embryos. In addition it should

by noted by users that quantitative measurements of embryo features are provided as approximations based on measures of a limited number of embryos. Variability around these values is to be expected, however, it is anticipated that they will provide useful benchmarks for embryo aging. Descriptions of embryos that died very early in development and infertile eggs are also provided to assist in distinguishing these eggs from viable eggs, either unincubated or partially incubated. In determining fertility, it may be most useful to compare the descriptions for infertile eggs and Day 0 (unincubated fertile) eggs below.

Days 0 to 4. Key diagnostic criteria include qualitative characteristics and diameter of the blastodisc and yolk sac membrane. Also observed during this period are the appearance of somites, head process, and heart, and establishment of the embryonic axis.

Day 0 Blastoderm appears as a solid white disc, 1.5 mm in diameter, having distinct edges surrounded by a darker region of yolk. Yolk sac may be 2-5 mm in diameter in pre-incubated eggs.

Day 1 Stage 2 (2-3). Blastoderm appears as a distinct white ring, 1.5 mm in diameter. Yolk sac may be 13 mm in diameter in pre-incubated eggs.

Day 2 Stage 4 (3-7). Primitive streak is distinct. The entire area pellucida/area opaca appears as a raised-domed structure protruding above the surrounding yolk.

Day 3 Stage 8 (6-10). Head-fold is visible at anterior end of embryo. At least four pair (4-9) of somites are visible. Area pellucida is 3 mm long and pear-shaped.

Day 4 Stage 13 (12-16). Blood islets surround embryo. Amniotic fold covers head to hindbrain. Otic pits are visible just above first somite. Head is turning over onto left side. Heart tube is beginning to loop.

Days 5 and Onward. Aging is based primarily on development of the head, limbs and tail, and position of the embryo on the yolk. Days 8-12 focus on eye, eyelid, brain size, limb length, neck length, and trunk length. Main diagnostic features from Day 25 to hatch are sloughing of the periderm, keratinization and length of nails and beak, eye diameter, etc.

Day 5 Stage 18 (18-19). *Eye:* Eye unpigmented,

- lens present, midbrain same size as eye. *Yolk*: Blood moving in yolk vasculature in response to heart tube contractions. *Heart*: Heart looped in full circle. *Limbs*: Wing and leg primordia are just visible. *Amnion*: Amnion may be closed but contains very little fluid. *Flexures*: Cervical flexure 90 degrees from trunk to midbrain (L-shaped). Embryo has turned onto left side from head down to mid-torso. *Tail*: Tail bud is cone-shaped and extends along main body axis.
- Day 6 Stage 20 (17–21). *Eye*: Eye faintly pigmented, with choroid fissure clearly visible. *Visceral arches*: Otic vesicle just dorsal to 2nd and 3rd visceral clefts. Midbrain slightly larger than eye. Nasal placodes have deepened into pits. *Limbs*: Both wings and legs are wider than long. *Amnion*: Amniotic sac sealed but contains very little fluid. *Flexures*: Completely turned onto left side. *Tail*: Tail bud is perpendicular to main body axis. *Allantois*: Allantoic sac just visible behind right leg bud.
- Day 7 Stage 23 (23–25). *Eye*: Eye heavily pigmented and lens clearly visible. Mandible is $\frac{2}{3}$ length of the maxillary process. *Limbs*: Wings and legs are as long as they are wide. *Amnion Flexures*: Embryo curved in a C-shape around the heart. *Tail*: Tail bud has a distinct ventral “hook” at the tip. *Allantois*: Allantoic sac highly vascularized, may cover the eye and forebrain.
- Day 8 Stage 25. *Beak*: Sides of the beak still separated from the tip by the nasal groove. *Visceral Arches*: Otic vesicle about same size as lens. Collar at the base of the neck is distinct and raised. *Limbs*: Elbow and knee joints distinct on limbs. Wing tip and foot area flattened into paddles but no digits are visible. Both wings and legs longer than wide. *Allantois*: Allantois covers head and part of the body.
- Day 9 Stage 27 (25–29). *Beak*: Tip of upper beak is a square protrusion. *Limbs*: Connective tissue just visible for tibia/fibula and radius/ulna. Wing middle digit longer than outer two with a slightly fan-shaped digital plate. Distinct grooves between toe primordia. Five toes visible. *Amnion*: Yolk vasculature at or approaching the albumen in the small end of the egg. Contractions of the amnion moderate and frequent. Amnion filling with fluid. *Allantois*: Allantois/Chorioallantoic membrane (CAM) covers embryo except along spine.
- Day 10 Stage 28 (27–29). *Beak*: Mandible is about $\frac{1}{2}$ the length of the maxilla and very square when viewed from front. Distinct falcon’s notch (i.e., tomial tooth) is visible just anterior to nasal groove. *Limbs*: Slight grooves visible between digits on wings. Alula is distinctly the shortest digit. *Feathers*: No distinct primordia, but scapular tract obviously raised.
- Day 11 Stage 30 (30–31). *Eye*: Nictitating membrane just visible at anterior corner of eye. Upper and lower eyelid folds just visible. Eye appears about the same size as midbrain. *Beak*: Mandible has distinct bend at midpoint and is about same length as maxillary process. *Visceral Arches*: Nares may be visible at top of nasal groove. *Limbs*: Legs now longer than the tail bud. Wing slightly bent at wrist. *Amnion*: Amnion mildly contractile. *Allantois*: CAM now extends over about $\frac{9}{10}$ of yolk sac vascular region. Allantois filled with mostly clear fluid.
- Day 12 Stage 32 (30–33). *Eye*: Eyelids covering about $\frac{1}{3}$ of eye. Approximately 2–8 scleral papillae visible. *Beak*: Distinct falcon’s tooth. Lower mandible is wider than upper mandible from frontal view. Egg tooth may be visible on top of beak. *Limbs*: Alula separated from wing tip. Fifth toe may be gone. *Feathers*: Two distinct rows of feather primordia on either side of spine. *Allantois*: Lobes of CAM starting to surround albumen at small end of egg.
- Day 13 Stage 32–34. *Eye*: 14 scleral papillae. Nictitating membrane about $\frac{1}{2}$ way across eyeball toward the scleral papillae. *Visceral Arches*: Nasal groove fused. Collar at the base of the neck flattened or gone. *Beak*: Distinct egg tooth. *Limbs*: Web well regressed between digits 2 and 3 on the foot. *Amnion*: Amnion is inflated with clear fluid. *Feathers*: Feather buds visible along spine, neck and scapular tracts and tail rectrices, pectoral tracts.
- Day 14 Stage 35. *Eye*: Nictitating membrane and upper eyelid almost to scleral papillae. *Limbs*: Toes well separated. Primary toe pads just visible. *Amnion*: Albumen starting

- to enter amniotic sac. *Tail*: Tail almost parallel with spine. *Feathers*: Feather buds visible on top of head, eyelids, thighs and back and along ulna. *Gonads*: Male and female gonads can be differentiated. Male gonads are bean-shaped. Left female gonad is flattened and translucent, and distinctly larger than right gonad.
- Day 15 Stage 36. *Eye*: Eyelid opening is flattened ellipse with lower lid at edge of cornea. *Feathers*: Primary feather buds just visible on manus. Feather buds just visible around ear opening.
- Day 16 Stage 36–37. *Eye*: Nictitating membrane at edge of cornea. *Limbs*: Primary toe pads well defined. First three scutate scales are on top of foot. Cornification just beginning on dorsal side of toenail. *Feathers*: Primaries and secondaries are longer than wide. *Allantois*: CAM sticks tightly to shell.
- Day 17 Stage 37. *Beak*: Groove at tip of mandible just visible. *Limbs*: Slight ventral curve to toenails. Legs tend to be crossed in front of body. *Allantois*: CAM may be closed over albumen. Allantoic fluid may be cloudy with precipitate.
- Day 18 Stage 38. *Beak*: Upper beak, but not lower beak, starting to cornify around egg tooth. Under side of lower beak (“chin”) is distinctly rounded. *Limbs*: Scale primordia covering tops of tarsus and tops of toes, not yet overlapping. Nail bed has distinct ridge at base of toenails. *Feathers*: Feather buds around ear. Two rows of eyelash feather buds. *Cloaca*: Cloaca distinctly raised and oval.
- Day 19 Stage 38. *Eye*: Lens partially covered by eyelids. *Beak*: Beak and face may be covered by a lobe of the yolk. Cross-shaped cornification centered around egg tooth. Small cornification on lower beak at tip of mandible. *Amnion*: Coagulated albumen sticking to embryo. *Limbs*: Scales starting to overlap along the front of the tarsus. Scales appearing along the back of tarsus and on primary toepads. Secondary toepads well-defined. Toenails strongly flexed on hallux. *Feathers*: Feather buds visible on cere. *Allantois*: Precipitate throughout allantoic sac.
- Day 20 Stages 38–40. *Eye*: Eye is almost closed. *Beak*: Periderm visible on beak. *Limbs*: Toenails flexed at a 90° angle to toe. *Amnion*: Yolk is in two distinct lobes on either side of the embryo. Only small amount of amniotic fluid remains. Amnion not contractile. *Allantois*: Allantoic fluid may be clear, but with precipitate.
- Day 21 Stage 40. *Eye*: Eyelids completely closed. *Beak*: Hole in periderm over egg tooth. Periderm may be starting to separate from cere. *Limbs*: Scales overlapping on the back of the tarsus. Scales on secondary toepads.
- Day 22 Stages 40–44. *Eye*: Eye is fully closed. *Beak*: Bony tubercle visible in nares. Tip of mandible is even with falcon’s tooth. Periderm may be starting to separate from cere. *Hatching muscle*: Hatching muscle starting to swell.
- Day 23 Stage 44. *Beak*: Beak cornification may be complete. Periderm is separating from the cere. Scalloping on side of mandible is diminished. Tip of mandible extends beyond falcon’s tooth. *Amnion*: Trace amount of albumen in small end of egg; most is in amniotic sac or sticking to the feathers. *Feathers*: Eyelash feathers much longer than wide. Feathers over entire body are filamentous and white.
- Day 24 Stage 44. *Head*: Head near air cell, may be under right wing, but not usually pipped. *Beak*: Periderm has sloughed about halfway from upper and lower beaks. Egg tooth may have started to wear through the CAM. *Limbs*: Nails are completely keratinized. *Amnion*: CAM easily separates from shell. *Allantois*: Most of allantoic fluid is gone. *Hatching muscle*: Maximum edema of hatch muscle, which may extend into the shoulder area. *Cloaca*: Cloaca is flattened oval, just raised above the surrounding skin.
- Day 25 Stage 44+. *Amnion*: Yolk just starting to enter abdomen. No fluid in amnion. *Flexures*: Head is under right wing. *Other*: First crack in shell near the equator.
- Day 26 Stage 45–. *Beak*: Periderm has sloughed. Entire beak appears shiny. *Allantois*: CAM often does not close completely over the albumen. Very little fluid in allantoic sac, just yellowish strings of urate precipitates. Almost no albumen remaining in the small end of the egg. *Yolk*: Sac is ¼ into abdom-

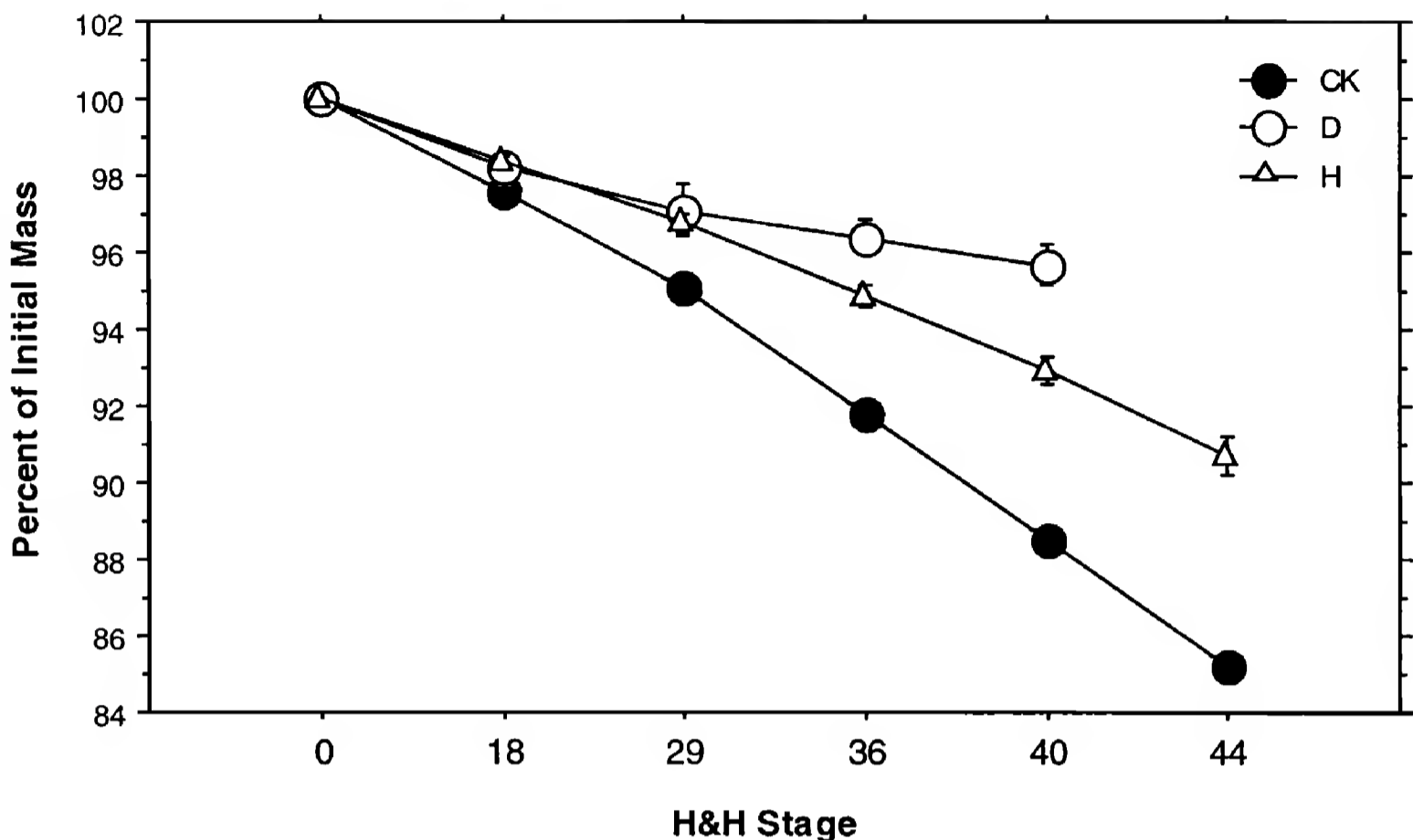


Figure 2. Egg mass loss as a percent of fresh egg mass (± 1 SE) of American Kestrel eggs developing to hatch (H), American Kestrel eggs failing before hatch (D), and normal chicken eggs (CK).

inal cavity. *Other*: Chick may have pipped into the air cell and may be vocalizing.

Day 27 Stage 45. *Beak*: Beak is in the air cell. *Al-lantois*: Most of the CAM blood vessels are empty. *Yolk*: Yolk may be completely inside of abdominal cavity. Typically, yolk will be orange-yellow in color. *Other*: Chick is peeping loudly and persistently.

Day 28 Stage 46. Hatched chick. Yolk fully internal.

Egg Mass Loss and Embryo Measurements.

American Kestrel eggs lost less mass as a percent of initial (i.e., fresh) egg mass at a slower pace than chicken eggs at comparable developmental stages (Fig. 2). When the embryo died during development, egg mass loss slowed (Fig. 2).

A number of embryo parameters were correlated with incubation day (Table 2). With the exception of yolk and albumen measures, relationships were positive. For each parameter, the ranges of incubation days over which the parameter-incubation day relationship was analyzed are shown in Table 2, and in general reflect the time period over which the parameter could be accurately measured.

DISCUSSION

This paper presents the first description of the daily embryonic development for a raptor species and provides a potentially useful tool for experimental and field assessments of the development of American Kestrels and possibly other raptors. Use of a species-specific guide is particularly important for identifying morphological abnormalities in embryos, which would not otherwise be apparent if comparisons were made to a taxonomically distant species (e.g., chicken). Such abnormalities may be indicators of embryo exposure to pathogens, genetic mutations, physical, thermal or nutritional stresses, or toxic concentrations of some chemicals (Romanoff and Romanoff 1972). In addition to assessment of normalcy, the external criteria described in this study can be used for estimating age in days, or equivalent Hamburger and Hamilton (1951) stage, in embryos that have been incubated and/or dead for unknown periods, such as those collected in the field. Clearly, some descriptions and measured parameters will be more practical than others depending on the condition of the embryo. In embryos that have been dead for some period, dehydration and decay may limit the utility of some of the visual and measured cri-

Table 2. Significant relationships observed between incubation day and egg and embryo measurements over the incubation period ($P < 0.001$). For each parameter, columns show range of incubation days over which measures were taken (Incubation Days), sample size (N), regression equation describing relationship with incubation day, X , r^2 value, and F statistic.

PARAMETER (X)	INCUBATION		EQUATION	r^2	F
	DAYS	N			
Air cell	0–26	68	$-21.03 + 2.03 (X)$	0.61	101.3
Eye diameter	5–28	79	$5.56 + 0.72 (X) + 0.106 (X)^2$	0.90	344.7
Brain vesicles/midbrain	5–13	27	$3.67 + 1.28 (X)$	0.89	208.6
Wing length	6–11	16	$4.79 + 1.44 (X)$	0.79	54.5
Mandible	7–28	58	$4.09 + 2.33 (X)$	0.95	1086.8
Trunk	7–28	63	$3.59 + 0.76 (X)$	0.96	1456.6
Yolk sac mass	8–28	47	$31.23 - 4.45 (X) + 0.211 (X)^2$	0.83	104.3
Yolk sac volume	8–28	48	$32.17 - 4.97 (X) + 0.267 (X)^2$	0.84	117.5
Albumen mass	8–24	37	$24.10 - 3.45 (X)$	0.78	122.9
Albumen volume	8–24	40	$24.22 - 3.82 (X)$	0.79	139.1
Embryo mass	9–28	53	$9.65 + 3.42 (X) - 0.174 (X)^2$	0.96	567.1
Eye-to-eye	9–28	62	$6.81 + 0.09 (X) + 0.050 (X)^2$	0.79	114.2
Third toe length	10–28	53	$5.96 + 2.28 (X)$	0.86	318.9
Alula	11–28	54	$5.51 + 3.65 (X)$	0.85	239.9
Forearm	11–28	56	$10.12 + 0.36 (X) + 0.073 (X)^2$	0.94	429.8
Manus	11–28	56	$10.26 + 0.34 (X) + 0.073 (X)^2$	0.92	304.2
Culmen	11–28	56	$6.52 + 2.94 (X)$	0.94	793.5
Tarsus	13–28	49	$8.43 + 1.43 (X)$	0.94	739.8
Tibia	13–28	49	$7.83 + 1.04 (X)$	0.96	989.7
Ear-to-ear	13–28	49	$12.04 - 0.28 (X) + 0.084 (X)^2$	0.87	149.8

teria described here. Parameters that may remain most useful for postmortem evaluation include limb and beak measurements, eye pigmentation, leg and foot development (e.g., scales, toenail keratinization), and feathering.

In a previous study, the embryonic development of the American Kestrel was described for selected days during incubation using naturally incubated eggs (Bird et al. 1984). Findings reported here for artificially incubated embryos compare favorably with the prior study with respect to timing of appearance of various external features (e.g., eye pigmentation, allantoic sac, development of toe digits, toenails, and down). A potential confounding factor in artificial incubation studies of embryos is the possible pre-incubation of eggs by parent birds before collection, which could result in an apparent advancement of embryo maturation, particularly at early stages of development. We controlled for this effect as much as possible by carrying out frequent egg collections, and excluding eggs that were relatively advanced, based on candling appearance, from early development examinations. Comparison of our results with those of the Bird et al.

(1984) study suggest that American Kestrel embryos developed at “normal” rates under the conditions of artificial storage and incubation we used.

The appearance of the germinal disc at the time of oviposition or before the onset of incubation can be used to determine fertility or early death. However, normal variations in size, shape, and color patterns may make it difficult to differentiate reliably between an infertile germinal disc and a developing blastoderm. Such variations have been described in great detail for the domestic turkey, (Bakst et al. 1998). Although precocial, the turkey shares several characteristics with the American Kestrel: an incubation period of 28 days, a blastodisc that typically appears as a circular, uniformly white structure (see Appendix 1; in contrast to the chicken blastodisc, in which the white area opaca is typically seen as a ring around the darker area pellucida), and the presence of small vacuoles surrounding the unfertilized germinal disc, which may closely resemble the fertile blastoderm in size, shape, and color. Thus, the morphological classes described in detail by Bakst et al. (1998) are a potentially useful guide to assessing fertility and ab-

normalities of American Kestrel germs at this very early period in development.

The chicken has long been used as a developmental standard for aging avian species (Hamburger and Hamilton 1951), and it is considered to be accurate for both precocial and altricial species up to stage 42 (about $\frac{2}{3}$ of the way through normal incubation; Ricklefs and Starck 1998). However, the chicken staging charts are not particularly useful in aging altricial embryos during the last $\frac{1}{3}$ of incubation, which is characterized by a rapid increase in size. Also, despite the utility of the chicken model, differences in morphology of key embryonic structures between the chicken and specialized altricial species, such as the American Kestrel, can make it difficult to assess incubation age accurately.

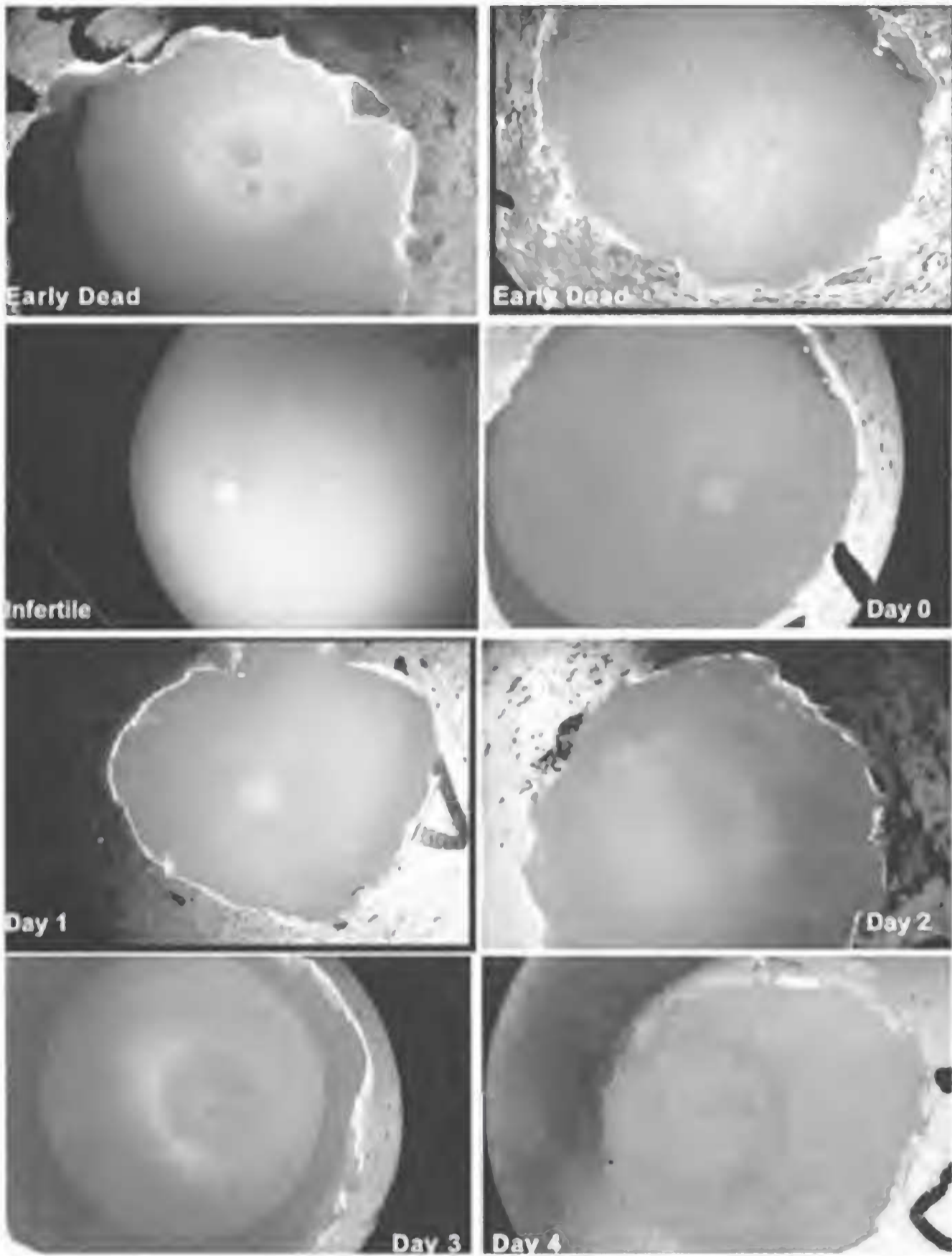
ACKNOWLEDGMENTS

Funding for this research was provided by the U.S. Bureau of Reclamation under contract number 9-CS-20S00440 for the Kesterson Reservoir biological monitoring program. Wild American Kestrels were trapped under California Department of Fish and Game Scientific Collecting Permit No. 801023-02. We thank the Center for Ecological Health Research at the University of California at Davis. We particularly thank S. Miller for graphics assistance, the UCD undergraduate students that helped with data recording, and F. Bradley for use of laboratory facilities.

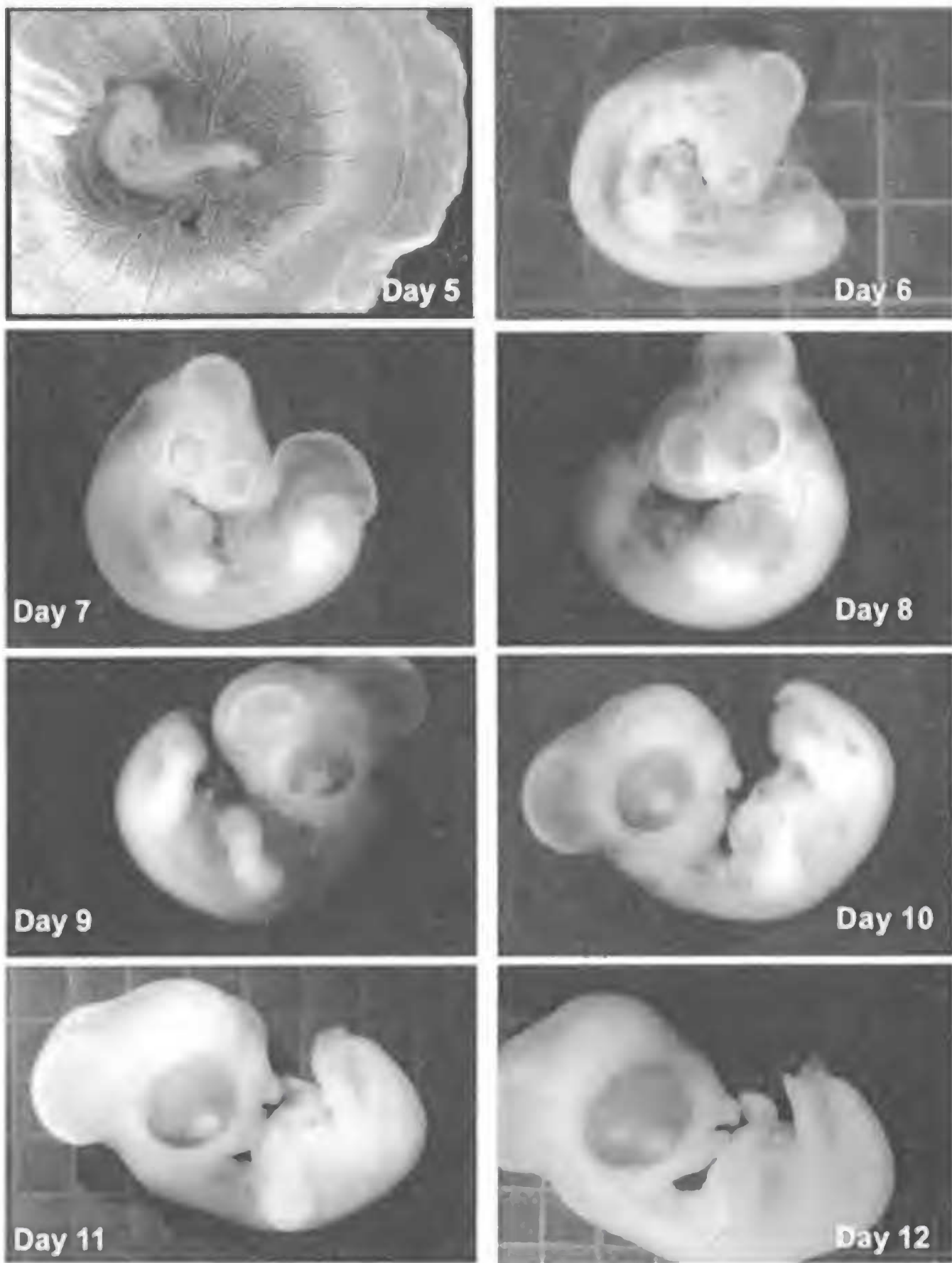
LITERATURE CITED

- ABBOTT, U.K. 1967. Avian developmental genetics. Pages 12–52 in F.W. Will and N.K. Wessels [EDS.], *Methods in developmental biology*. Thomas Y. Crowell Co., New York, NY U.S.A.
- , B. CUTLER, A.T. BRICE, AND J.R. MILLAM. 1991. Development of the Cockatiel embryo. *J. Assoc. Avian Vet.* 5:207–209.
- BIRD, D.M., J. GAUTIER, AND V. MONTPETIT. 1984. Embryonic growth of American Kestrels. *Auk* 101:392–396.
- BAKST, M.R., S.K. GUPTA, W. POTTS, V. AKUFFO. 1998. Gross appearance of the Turkey blastoderm at oviposition. *Poult. Sci.* 77:1228–1233.
- BELLAIRS, R. AND M. OSMOND. 1998. *The atlas of chick development*. Academic Press, San Diego, CA U.S.A.
- CALDWELL, P.J. AND A.E. SNART. 1974. A photographic index for aging Mallard embryos. *J. Wildl. Manage.* 38:298–301.
- DANIEL, J.C. 1956. A comparative study of the embryological development of the domestic fowl and the Red-winged Blackbird. Ph.D. dissertation, University Colorado, Boulder, CO U.S.A.
- HAMBURGER, V. AND H.L. HAMILTON. 1951. A series of normal stages in the development of the chick embryo. *J. Morphol.* 88:49–92.
- HAMILTON, H.L. 1952. *Lillie's development of the chick*. Henry Holt and Co., Inc., New York, NY U.S.A.
- HANBIDGE, B.A. AND G.A. FOX. 1996. Egg characteristics, growth and developmental landmarks of known-age embryos of Double-crested Cormorants from Manitoba. *Colon. Waterbirds* 19:139–142.
- HECK, W.R. AND D. KONKEL. 1991. Incubation and rearing. Pages 34–76 in J.D. Weaver and T.J. Cade [EDS.], *Falcon propagation: a manual on captive breeding*. The Peregrine Fund, Boise, ID U.S.A.
- HERBERT, C. 1967. Timed series of embryonic developmental stages of the Adelie Penguin (*Pygoscelis adeliae*) from Signy Island, South Orkney Islands. *Br. Antarct Surv. Bull.* 14:45–67.
- HERMES, J.C. AND A.E. WOODARD. 1987. Development of the pheasant embryo: A record of daily visual changes. University of California, Department of Avian Sciences. 1m-pr-8/87-LE/ALS, Davis, CA U.S.A.
- LABISKY, R.F. AND J.F. OPSAHL. 1958. A guide to aging of pheasant embryos. Illinois Natural History Survey Division. Biological Notes No. 39, Urbana, IL U.S.A.
- RICKLEFS, R.E. AND J.M. STARCK. 1998. Embryonic growth and development. Pages 31–55 in J.M. Starck and R.E. Ricklefs [EDS.], *Avian growth and development*. Oxford University Press, New York, NY U.S.A.
- ROMANOFF, A.L. AND A.J. ROMANOFF. 1972. *Pathogenesis of the avian embryo*. Wiley-Interscience, New York, NY U.S.A.
- ROSEBERRY, J.L. AND W.D. KLIMSTRA. 1965. A guide to age determination of Bobwhite Quail embryos. Illinois Natural History Survey Division. Biological Notes No. 55. Urbana, IL U.S.A.
- SAS INSTITUTE. 1998. StatView reference. Release 5.0. SAS Institute, Cary, NC U.S.A.
- SANTOLO, G.M., J.T. YAMAMOTO, J.M. PISENTI, AND B.W. WILSON. 1999. Selenium accumulation and effects on reproduction in captive American Kestrels fed selenomethionine. *J. Wildl. Manage.* 63:502–511.

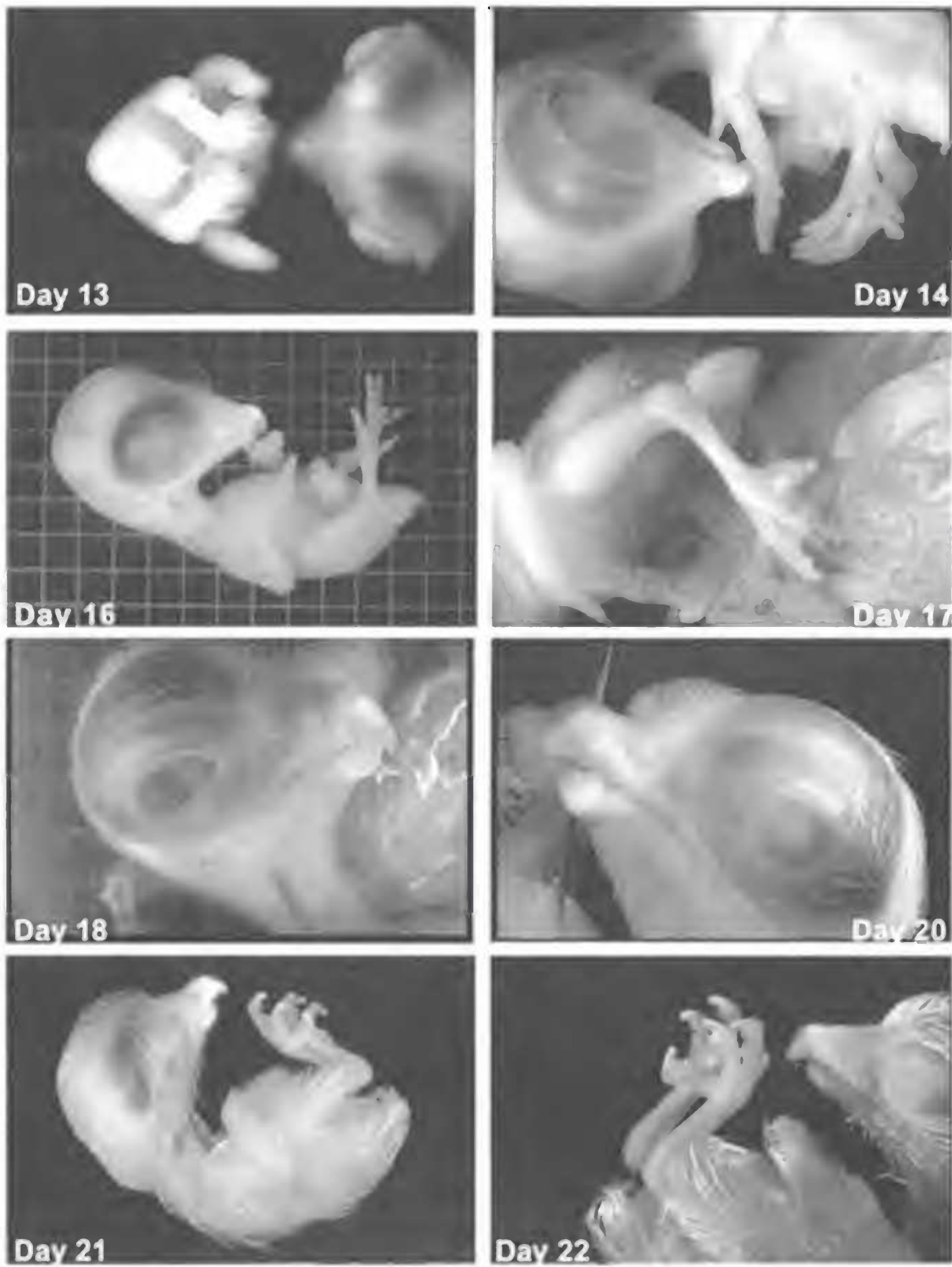
Received 23 June 2000; accepted 23 April 2001



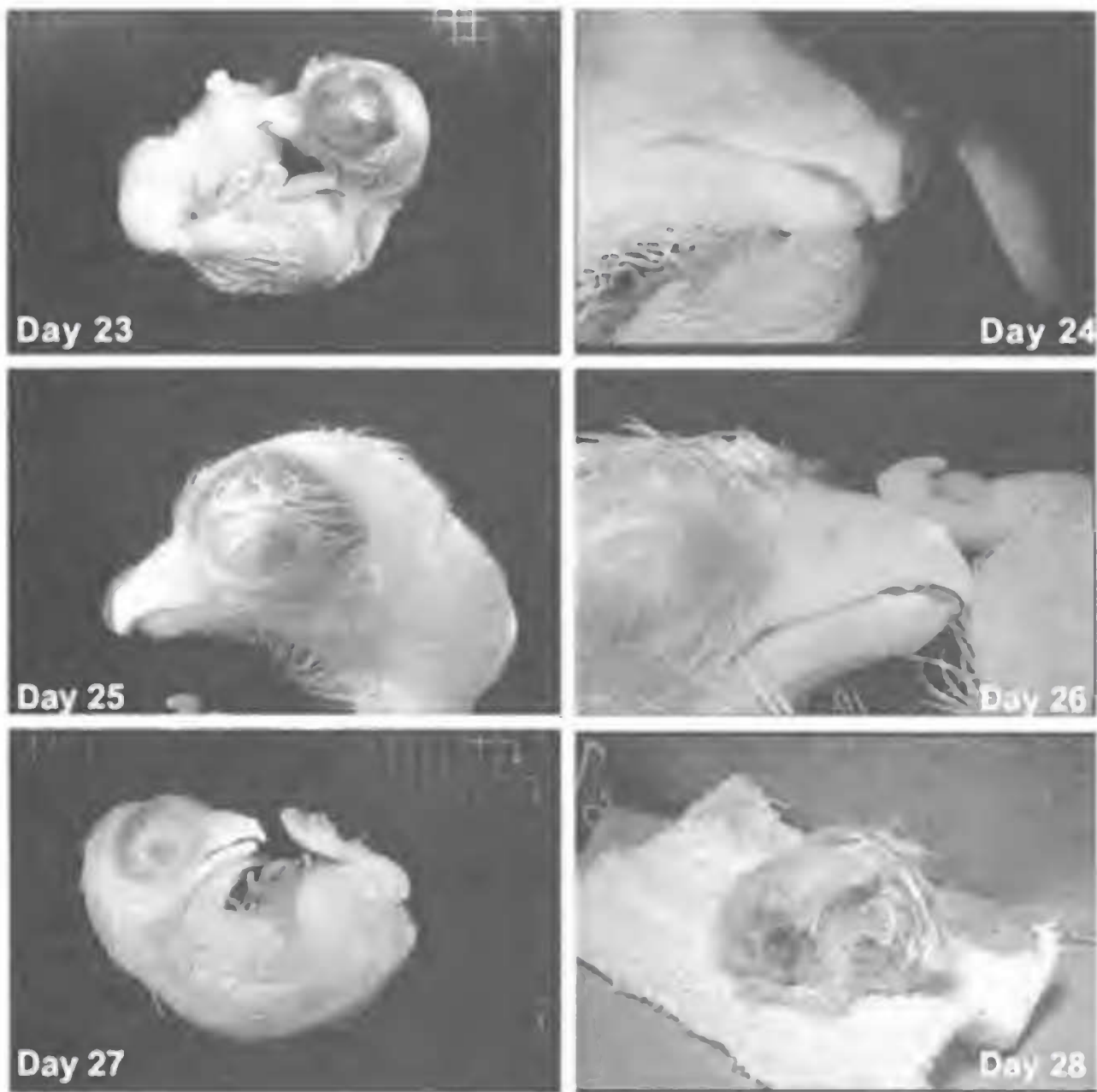
Appendix 1. American Kestrel egg contents and embryos from 0–4 d.



Appendix 2. American Kestrel embryos from 5–12 d.



Appendix 3. American Kestrel embryos from 13–22 d.



Appendix 4. American Kestrel embryos from 23–28 d.